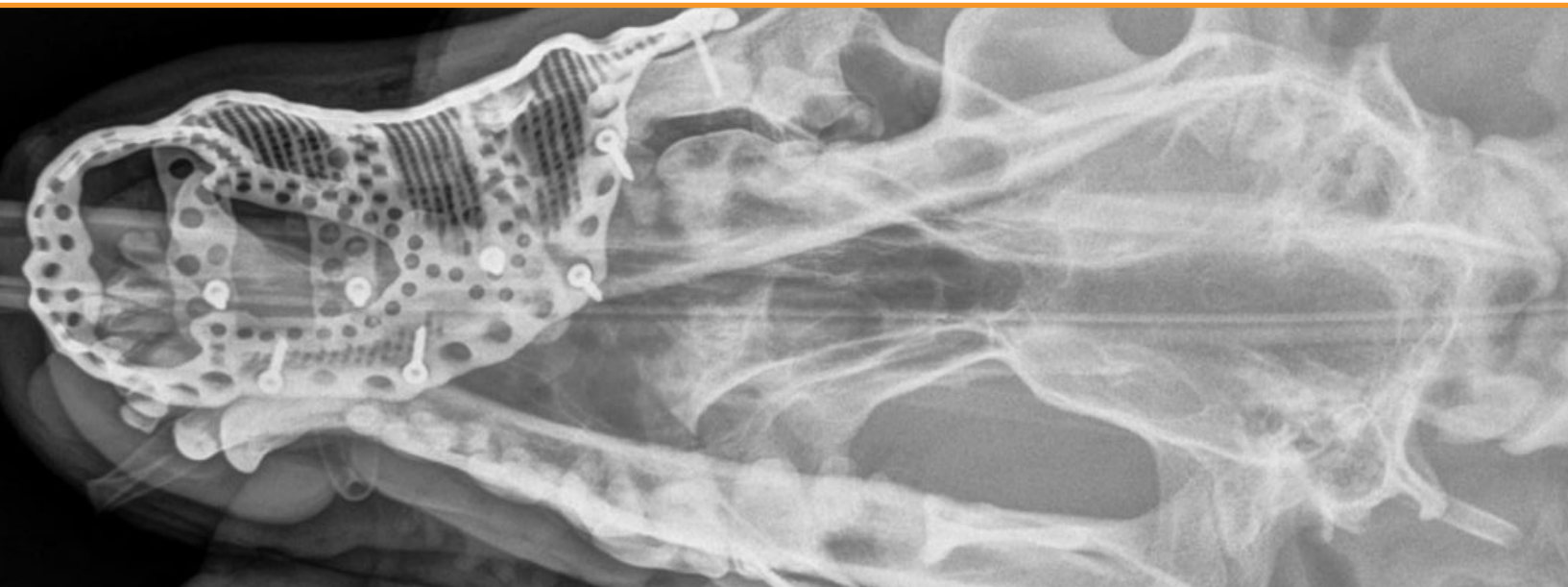


Additive manufacturing in veterinary surgery - saving a well-loved member of the family


Customer:

Julius Liptak

Industry:

Medical and healthcare

Challenge:

Seven year old Bernese Mountain Dog requiring excision of maxillary tumour.

Solution:

Design and manufacture a custom implant to replace the removed tissue.

Executive summary

A truly international effort, involving input from Germany, Canada and the UK has seen additive manufacturing (AM), also known as metal 3D printing, used to great effect to help save a Canadian family's dog.

In a recent procedure, Renishaw helped to produce an implant designed by Voxelmed in Germany that was fitted in Canada, to replace the hard tissue lost due to tumour removal.

In the past, hospitals would only use patient specific implants (PSIs) for complex cases, but now — thanks to advances in technology — they are becoming part of standard practice.

One of the most effective ways of producing a custom PSI is by using additive manufacturing (AM) with medical-specific CAD tools for the custom design.

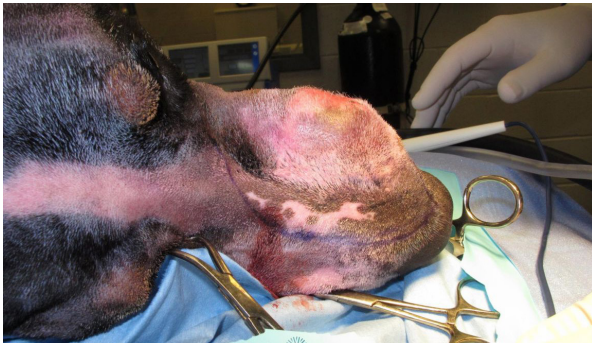Background

More than 50 per cent of dogs over ten years of age are likely to develop a tumour. Often, tumours can be shrunk with chemotherapy and removed with surgery without excessive long-lasting trauma. However, in some cases the placement of the tumour is too difficult to operate on without severely impacting the quality of life for the dog.

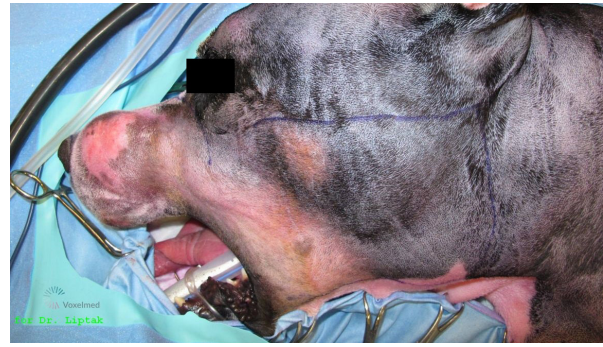In the human world there has been a significant shift towards surgeons using customised implants to help improve the results of surgery and reduce patient recovery times.

// Without additive manufacturing technology, it would have been impossible to reconstruct the dog's maxilla after tumour removal, because the area was extremely complex in geometry. //

Alta Vista Animal Hospital, Ottawa, Canada



Dog being prepared for surgery



Surgery image showing incision marks

Challenge

A seven-year-old Bernese Mountain Dog with a tumour on the left side of his maxilla (upper jaw) had few options other than total excision of the growth followed by reconstruction. A customised 3D printed titanium implant supporting the dog's bone structure was the most appropriate treatment due to the complexity of the region, requiring significant design and manufacturing freedom.

PSIs have predominantly been used in human cases to date, but global engineering and healthcare technologies company, Renishaw, and 3D design experts, Voxelmed, hope that this case will highlight the benefits of additive manufacturing in veterinary surgery.

Solution

The procedure, which was carried out by Julius Liptak, veterinary surgeon at Alta Vista Animal Hospital in Ottawa, Canada, used an additively manufactured titanium maxillofacial implant designed by Voxelmed, based in Germany. Using Digital Imaging and Communications in Medicine (DICOM), a standard that enables the integration of medical imaging devices, a digital 3D model of the dog's affected area was generated. The model was used to design a custom implant with input from Dr. Liptak.

During the design of the implant, Dr. Liptak reviewed the design repeatedly to compare it to 3D scans and models of the dog's skull. This made the process of manufacturing and placement much more straightforward, as it met the surgeon's specifications for how the implant would fit.

Dr. Liptak was able to plan the procedure in advance, streamlining the process and reducing the time that the dog was under anaesthetic.

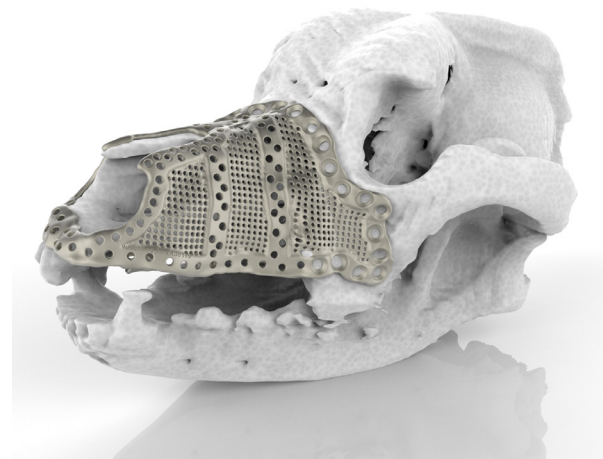
The implant was manufactured at the Additive Design in Surgical Solutions (ADEISS) centre in London, Ontario, Canada.

ADEISS is the result of a partnership between Western University, the London Medical Network and Renishaw. The centre will focus on the research, development and commercialisation of additively manufactured medical devices and surgical instruments. It will also aid in the development of additively manufactured medical technology to address healthcare issues across the globe.

"During surgery, the affected areas, along with clean tumour margins, were removed," explained Jan Klasen, veterinary surgeon, 3D designer and CEO of Voxelmed. "Because the tumour occurred in the skin, rather than the maxillary bone, resection involved a revision maxillectomy with excision of the 45 mm x 50 mm mass, with 30 mm lateral margins. The implant was then put into place and fixed with surgical screws. A facial axial pattern skin flap was prepared and used to cover the affected area and the implant. This left the dog with a particularly impressive physical outcome as the nose structure did not have to be altered to account for the missing tissue."



Showing implant design in isolation



Implant shown on model for pre-surgery planning

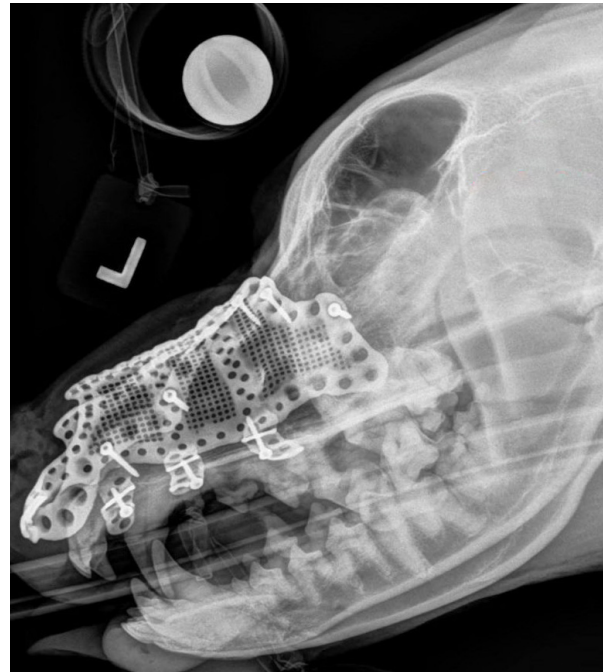
The design and manufacture of the implant took just two weeks to complete. In this particular case, the dog was suffering with ongoing tumour growth. So, if the implant had taken too long to be produced it would have no longer been fit for purpose as the affected area would have grown.

Results

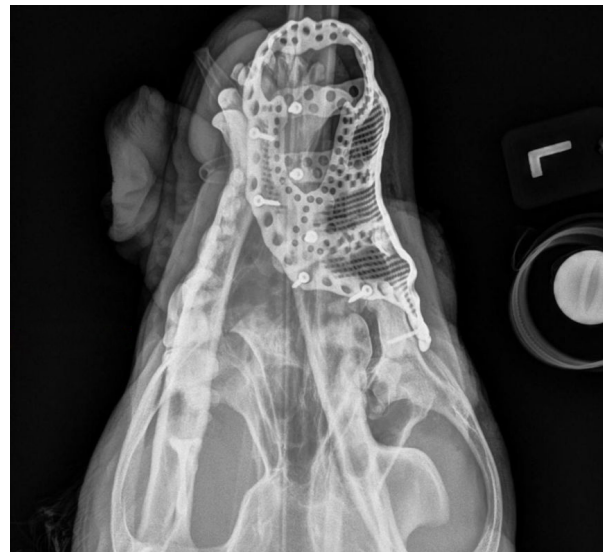“Without additive manufacturing technology, it would have been almost impossible to reconstruct the dog’s maxilla after tumour removal, because the area was extremely complex in geometry,” Klasen commented. “The implant had to have a similar shape and functionality as the dog’s existing bone structure. Using additive manufacturing to maintain the original shape and function of the oral and nasal cavity ensures a high quality of life for the dog, just as a naturally shaped skull and maxilla helps the dog to breathe and eat easily.

“To my knowledge, this is the first implant of its kind. Prior to this case, the majority of veterinary surgeons were unaware that the technology was even available. Similar reconstructions are now being planned in Germany and there is ongoing research into how animals can benefit from this procedure.”

The seven-year-old Bernese Mountain Dog was able to leave the hospital just one day after surgery. While he spent a little time taking pain medication and antibiotics he was able to breathe normally through his nose and has since made a full recovery. Without the advancements in additive manufacturing, this dog would not have such a long and happy future ahead of him.



Side view x-ray image with implant in position



Top down x-ray image with implant in place



Views of implant showing the complexity of design required

For more information visit www.renishaw.com

Renishaw plc
New Mills, Wotton-under-Edge
Gloucestershire, GL12 8JR
United Kingdom

T +44 (0) 1453 524524
F +44 (0) 1453 524901
E uk@renishaw.com
www.renishaw.com

For worldwide contact details, visit www.renishaw.com/contact

RENISHAW HAS MADE CONSIDERABLE EFFORTS TO ENSURE THE CONTENT OF THIS DOCUMENT IS CORRECT AT THE DATE OF PUBLICATION BUT MAKES NO WARRANTIES OR REPRESENTATIONS REGARDING THE CONTENT. RENISHAW EXCLUDES LIABILITY, HOWSOEVER ARISING, FOR ANY INACCURACIES IN THIS DOCUMENT.

© 2017 Renishaw plc. All rights reserved.

Renishaw reserves the right to change specifications without notice.

RENISHAW and the probe symbol used in the RENISHAW logo are registered trade marks of Renishaw plc in the United Kingdom and other countries. **apply innovation** and names and designations of other Renishaw products and technologies are trade marks of Renishaw plc or its subsidiaries. All other brand names and product names used in this document are trade names, trade marks or registered trade marks of their respective owners.



H - 5489 - 9060 - 02

Part no: H-5489-9060-02-A
Issued: 12. 2017